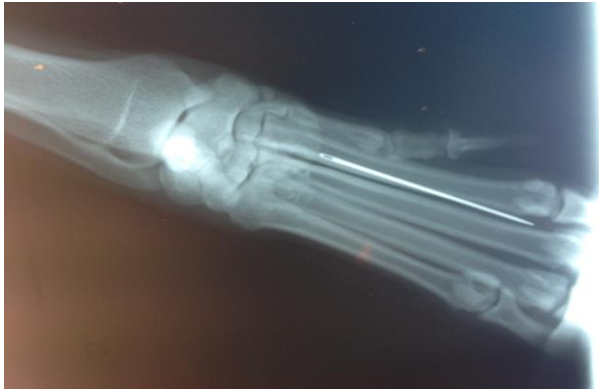


## *West Lakeland Veterinary Group*

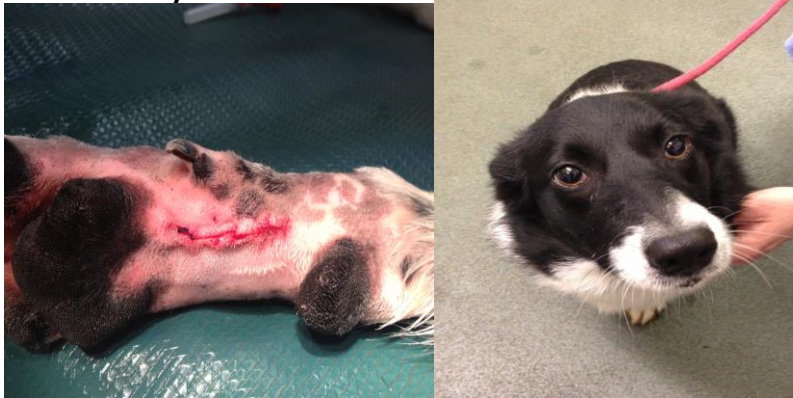

Megan is a 3 and a half year old border collie who presented at the clinic with lameness of the the front right leg. The pain was localised to the carpal (wrist) region. Anti-inflammatory medication did not resolve the lameness so she was admitted to the clinic for investigation .



Can you spot the problem ???

It is clear from her X-ray that a sewing needle has at some point become imbedded in the foot. The entry wound had long since healed without trace. She was taken to surgery for removal



A pleased looking megan can't wait to go home

